

TRICHOMONADS IN THE GOLDEN HAMSTER

WAYNE W. WANTLAND

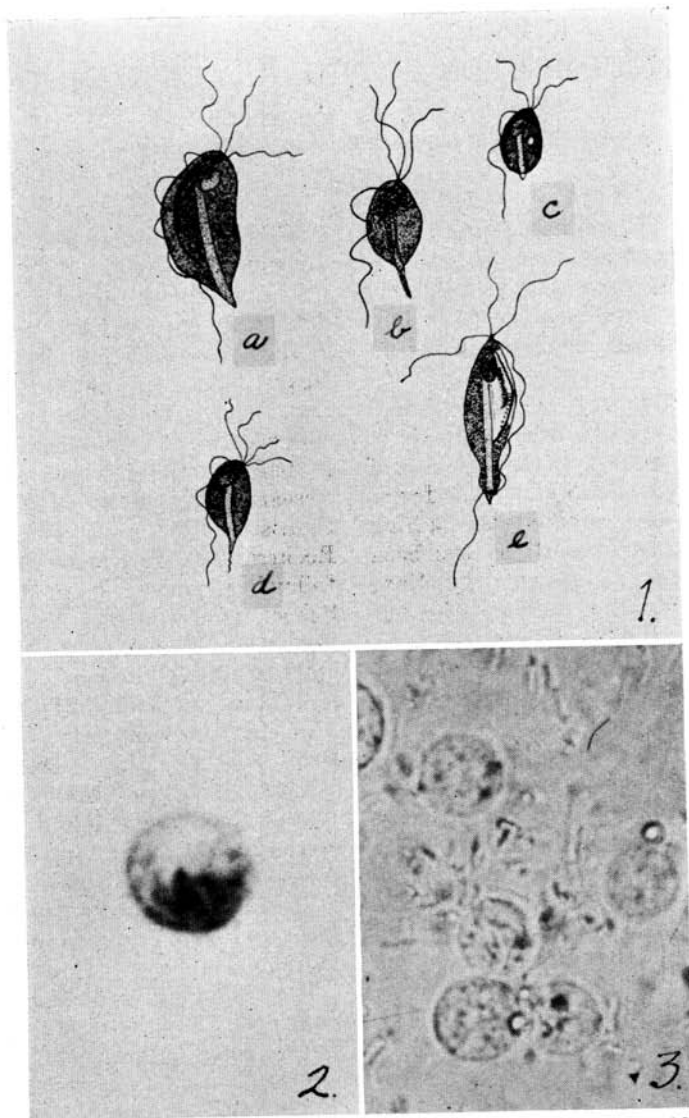
Illinois Wesleyan University, Bloomington

A study of parasitic fauna in 500 golden hamsters, *Cricetus auratus* (Waterhouse) from eight sources has revealed a high incidence (98.4%) of trichomonad flagellates in the digestive tract, particularly in the caecum. It is well established that rodents, as well as other animals in nature, commonly harbor species of mastigophora. Many of these forms show little host specificity and a high degree of transfaunations has been demonstrated in rodents by Saxe (1950). Wenrich (1946) who has done a prodigious amount of work on protozoa of rodents, especially trichomonads, is inclined to consider most of the protozoa found in the intestine of the hamster as identical with those found in rats. However, the evidence thus far is not entirely conclusive and much remains to be done in the way of transfaunation studies and tests of host specificity of these forms. Wenrich (1946) reported from observations made on one hamster, the finding of a *Trichomonas muris*-like form, as well as flagellates resembling *Trichomonas minuta*, *Trichomonas wenyoni*, *Giardia muris*, and *Chilomastix bettencourti*. Wenrich and Saxe (1950) reported success in infecting two trichomonad-free hamsters with a small trichomonad originally obtained from a vole, *Microtus pennsylvanicus*. The name *Trichomonas microti* was proposed for this flagel-

late by these authors and it was first described by them.

The following report is the result of a study supported in part by the Medical Research and Development Board, Office of the Surgeon General, Department of the Army, under contract No. DA-49-007-MD-495 and in part by the Division of Dental Research, School of Medicine and Dentistry, University of Rochester, Rochester, N. Y. Hamsters from the following sources were examined: School of Med. and Dent., Univ. Rochester, Rochester, N. Y.; School of Dent. Med., Harvard Univ., Boston, Mass.; School of Dent., Univ. Ala., Birmingham, Ala.; School of Dent., Univ. Minn., Minneapolis, Minn.; Division of Dental Research, Walter Reed Army Hospital, Washington, D. C.; Dept. of Biol., Ill., Wesleyan Univ., Bloomington, Ill.; Gulf Shores Hamstery, Gulf Shores, Ala.; and Gen. Biol. Supply House, Chicago, Ill.

The following trichomonads were identified: *Trichomonas muris*, *Trichomonas wenyoni*, *Trichomonas minuta*, *Trichomonas microti*, and a trichomonad apparently unlike any reported in the literature. This latter organism exhibits a more elongated, slender shape, measuring 12 to 25 μ in length by 5 to 10 μ in width. This form possesses three anterior flagella, a heavy, full body-length costa, an anteriorly located



FIGURES 1a, 1b, 1c, 1d, and 1e are photomicrographs of camera lucida drawings of iron-hematoxylin-stained specimens, X 1500. FIG. 1a.—*Trichomonas muris* trophozoite; note thick, pear-shape and heavy, full body-length costa; FIG. 1b.—*Trichomonas wenyoni* trophozoite; note free posterior portion of undulating membrane and long posterior projection of axostyle; FIG. 1c.—*Trichomonas minuta* trophozoite; note small size, short posterior projection of axostyle and chromatic ring at point of emergence of axostyle from body; FIG. 1d.—*Trichomonas microti* trophozoite; note presence of four anterior flagella and long filamentous end of axostyle; FIG. 1e.—*Trichomonas cricetus* trophozoite; note long slender body, posterior bulbar expansion, and chromatic ring at point of emergence of axostyle. FIG. 2.—Stained cyst of trichomonad; note remnant of undulating membrane within cyst wall, X 2000. FIG. 3.—Unstained cysts of trichomonads; cystic stages formed by subjecting trophozoites to artificial gastric juice; note definite cyst walls, X 1800.

nucleus, and a relatively long, club-shaped parabasal body. Metachromatic granules are heavy and numerous. A chromatic ring is present. A bulbar expansion of the posterior end near the point where the broad axostyle emerges, together with the slender shape of the body, differentiates this trichomonad from the other forms. The name *Trichomonas cricetus* is proposed for this trichomonad.

All examinations were done at autopsy and no attempt was made to establish percentages of the different species of trichomonads observed. *Trichomonas muris* was the most prevalent, with smaller numbers of the other species interspersed in wet smears of material prepared for examination. Trichomonads were present in greatest concentration in the caecum of hamsters, but they were also observed in smaller numbers in the duodenum and occasionally in the stomach and lower oesophagus. The trophozoite forms of trichomonads observed are shown in Figure 1. A detailed comparison of these species is shown in Table 1.

Multiplication of these trichomonads occurs by binary fission, and rarely a somatella is observed, indicating multiple fission. Considerable difference of opinion exists among parasitologists (Wenyon, 1926; Hegner *et al.*, 1938; and Chandler, 1952) with reference to formation of cysts by trichomonads. In this study, cyst-like bodies were definitely observed in all forms of trichomonads obtained from hamsters. These spherical bodies measuring from 7 to 13 μ in diameter were noted periodically in small numbers in normal feces and in excessive numbers in feces from ham-

sters fed a sunflower seed diet for three days or given stale bread soaked in a saturated solution of magnesium sulphate (Figs. 2 and 3). The writer is inclined to look upon these bodies as true cysts because of their appearance, method of formation, and quiescence. In wet preparations from the caecum, trophozoite forms can be observed to pass into the cystic stage as the preparation dries. The active forms thrash their flagella wildly, and wave-like movements of the undulating membrane increase in speed for a time. All movements gradually become slower and finally a few spasmodic waves of the undulating membrane envelop the posterior part of the axostyle, pulling it into the cyst. Trophozoites placed on a slide with artificial gastric juice encyst within a matter of minutes. Upon the addition of two or three drops of five per cent aqueous solution of pancreatin, movements can again be observed. The organism first begins to revert to the trophozoite form by a twisting, churning action within the cyst wall. As the action of pancreatin proceeds, the whole organism rotates within the cyst and movements of the undulating membrane can be seen. During a period of one to two hours following the addition of pancreatin the undulating membrane increases its movements. The body of the organism assumes various shapes, the flagella and the posterior part of the axostyle appear, and finally the trophozoite exhibits the characteristic locomotion of this stage of development.

Hamsters are born trichomonad-free. No hamsters under six days of age have been found infected with these parasites in this laboratory.

TABLE 1.—Comparison of the Species of Trichomonads from the Golden Hamster.

Shape	T. muris		T. wenyoni	T. minuta	T. microti	T. cricetus
	length	width				
Size, microns	16-26	10-14	6-16 2.5-6	4-8.5 2-4.5	4-10 2-4.5	12-25 5-10
Shape	thick, pear shape		lemon or pear shape	small lemon or pear shape	small lemon or pear shape	slender, elongated post. bulbar expansion
No. anterior flagella	3		3	3	4	3
No. waves in undulating membrane	5-6; membrane long as body		2-3; membrane .5-67 body length	3; membrane long as body	3-4; membrane long as body	5-6; membrane long as body
Costa	heavy; thick; long as body		slender; obscure	narrow; slight; long as body	narrow; slight; long as body	heavy; long as body
Axostyle	broad; hyaline; short post. protrusion from body		compact; tapering; post. protrusion from body	broad; hyaline; short post. protrusion from body	relatively broad; long, pointed post. protrusion from body	broad; short post. protrusion from body
Nucleus	anterior; oval		anterior; round or oval	anterior; round or oval	anterior; round	anterior; oval
Parabasal body	thick rod or club shaped		slight; delicate	short; slender	rod or Y-shaped	short; club shaped
Blepharoplast	small		relatively large	relatively large	small	large
Metachromatic granules	heavy, coarse; a long costa; perinuclear		heavy, coarse; ant. area	sparsely located along costa	sparsely located, perinuclear	heavy, coarse; along costa
Chromatic ring	not distinct		absent	present	absent	present

Initial infection occurs after the young become somewhat more active and begin to crawl and lick the perianal region of the mother as well as feces dropped by her. Older hamsters probably re-infect themselves by eating their own feces containing cysts; continued fission in the small intestine and caecum results in tremendous numbers of trichomonads. Marked hyperemia of the intestinal wall, with pin-point entorrhagia, was observed in many heavily infected animals, and erythrocytes were demonstrable in trophozoites. Evidence to date indicates that, in cases where the hamster host is weakened (certain nutritional experiments, surgery, etc.) and trichomonads are present in large numbers, a wasting diarrhea

appears. The result is death in many instances. Wantland and Johansen (1954) reported the feeding of a high protein diet and the administration of carbarsone as effective treatments in removing these flagellates from infected hamsters.

Since definite pathogenicity has been established in infections with various other trichomonads and in view of the above findings in the hamster it seems prudent to: (1) consider possible effects of the presence of these parasites in hamsters in the interpretation and evaluation of data from the many and varied experiments on this rodent; and (2) exercise precautionary measures against possible infection of laboratory workers with these protozoa.

LITERATURE CITED

- CHANDLER, A. C. 1952. Introduction to parasitology. John Wiley and Sons, Inc., New York. 756 pp.
- HEGNER, R. W., F. M. ROOT, D. L. AUGUSTINE, and C. G. HUFF. 1938. Parasitology. D. Appleton-Century Co., Inc., New York. 812 pp.
- SAXE, L. H. 1950. Transfaunation studies on the host specificity of the enteric protozoa of rodents. Jour. Parasit., 36(6) Sect. 2 (Suppl.):21-22.
- WANTLAND, WAYNE W., and ERLING JOHANSEN. 1954. Effect of carbarsone, chiniofon and high protein diet on trichomonads in the intestine of the golden hamster. Jour. Parasit., 40:479-480.
- WENRICH, D. H. 1946. Cultural experiments on intestinal flagellates. I. Trichomonad and other flagellates obtained from man and certain rodents. Jour. Parasit., 32:40-53.
- WENRICH, D. H., and L. H. SAXE. 1950. *Trichomonas microti*, N. S. P. (Protozoa, Mastigophora). Jour. Parasit., 36:261-269.
- WENYON, C. M. 1926. Protozoology. William Wood and Co., New York. 1563 pp.